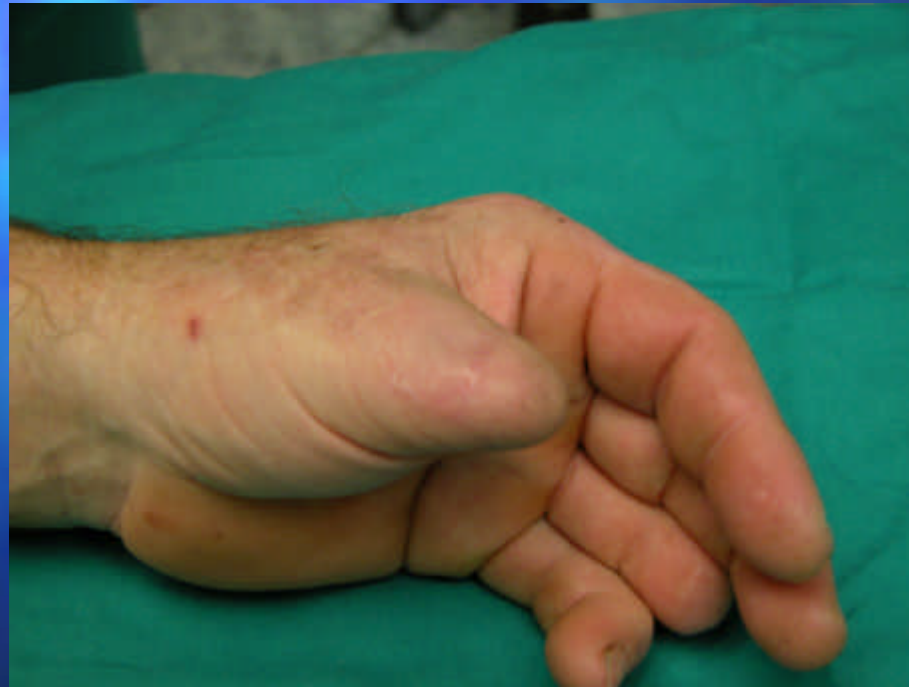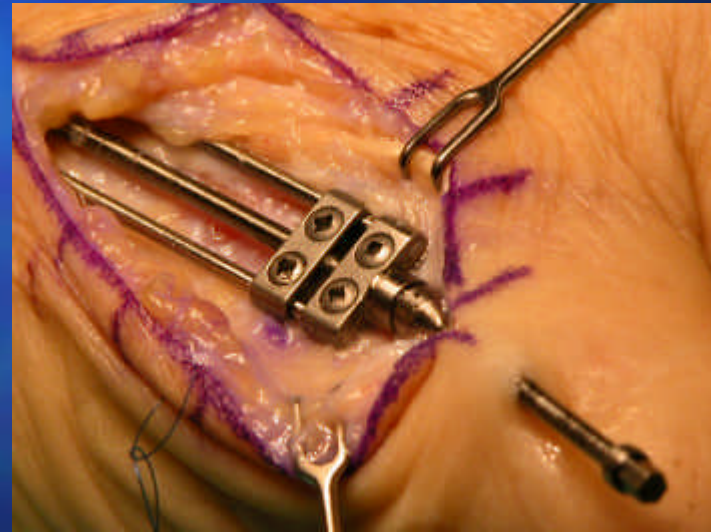
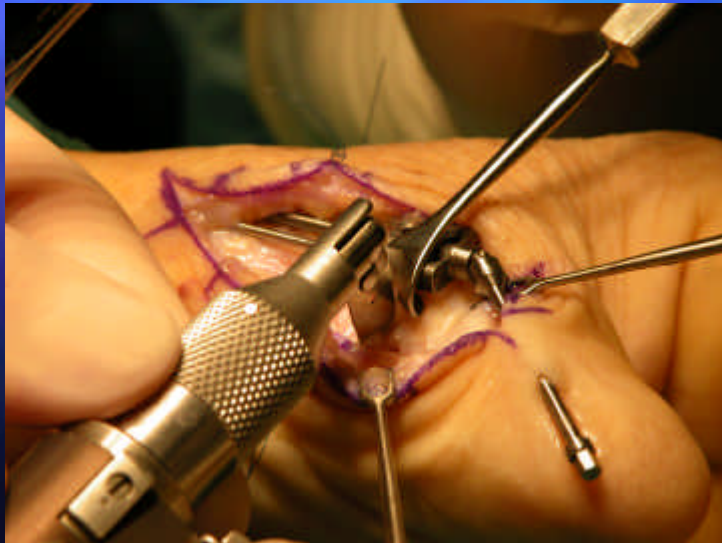
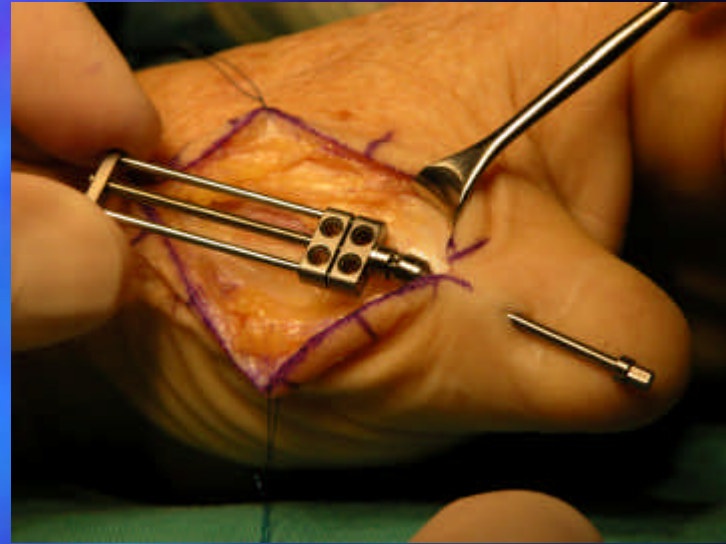
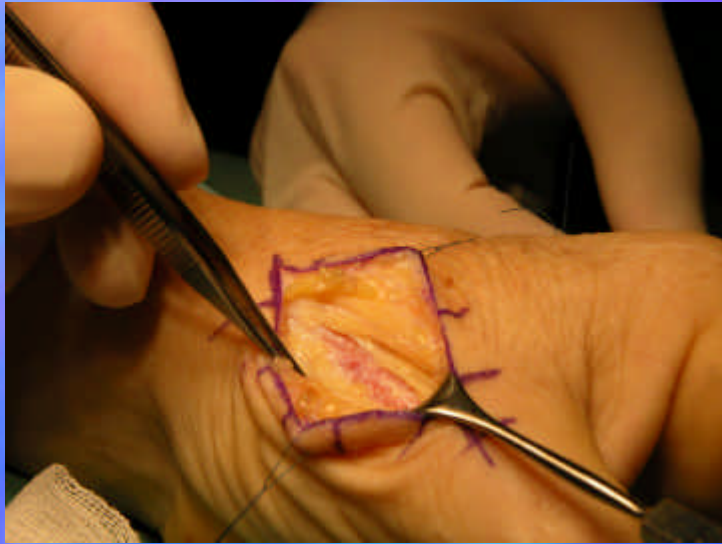


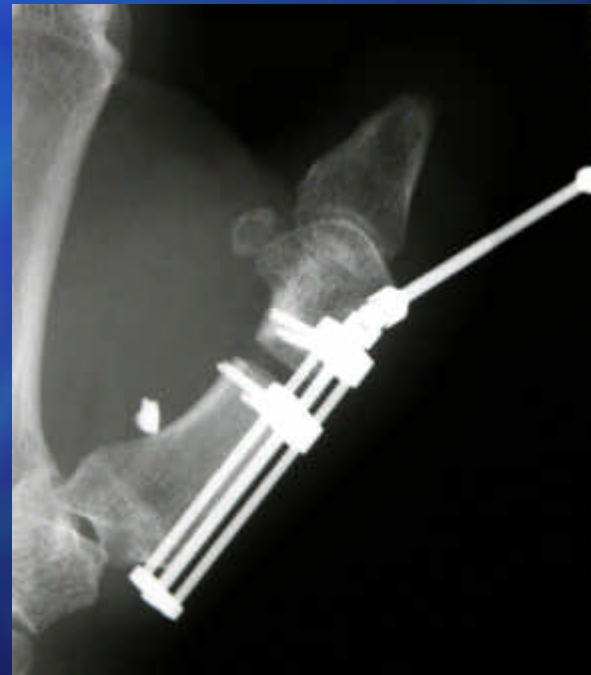
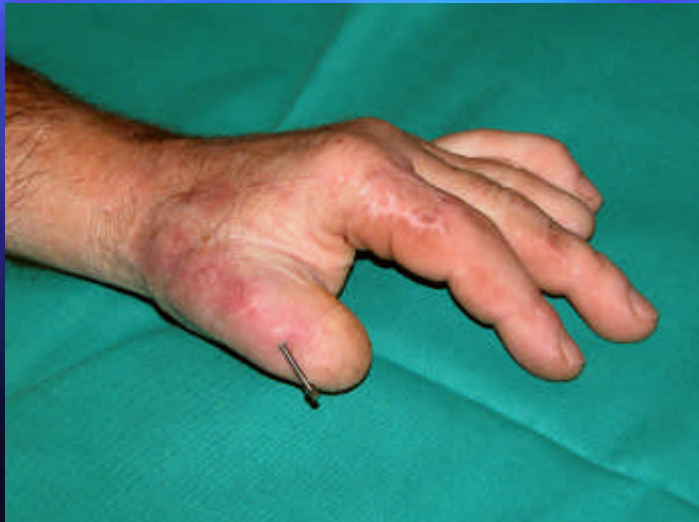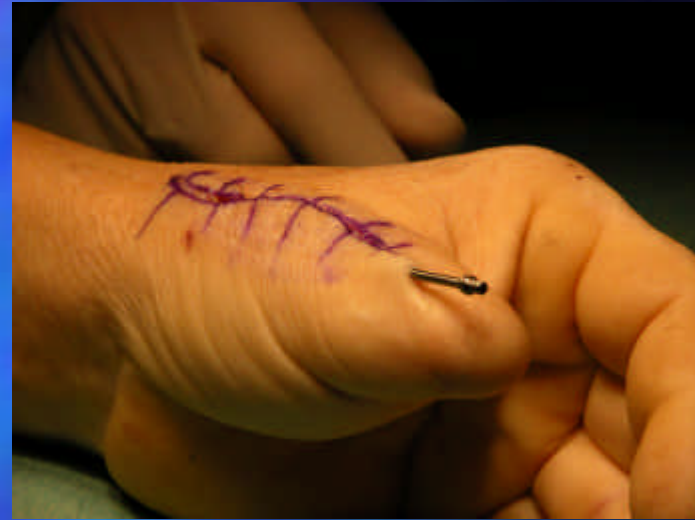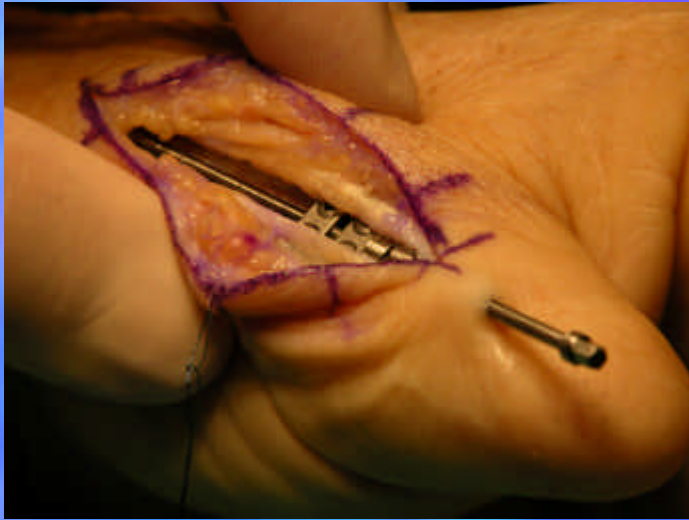
# Neues aus der Handchirurgie

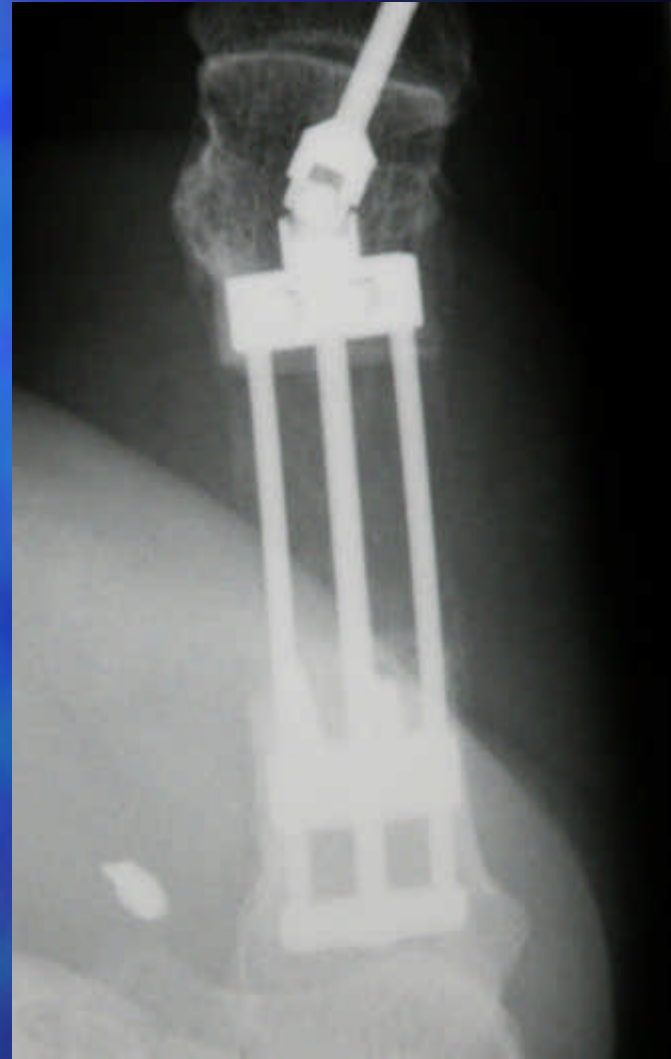
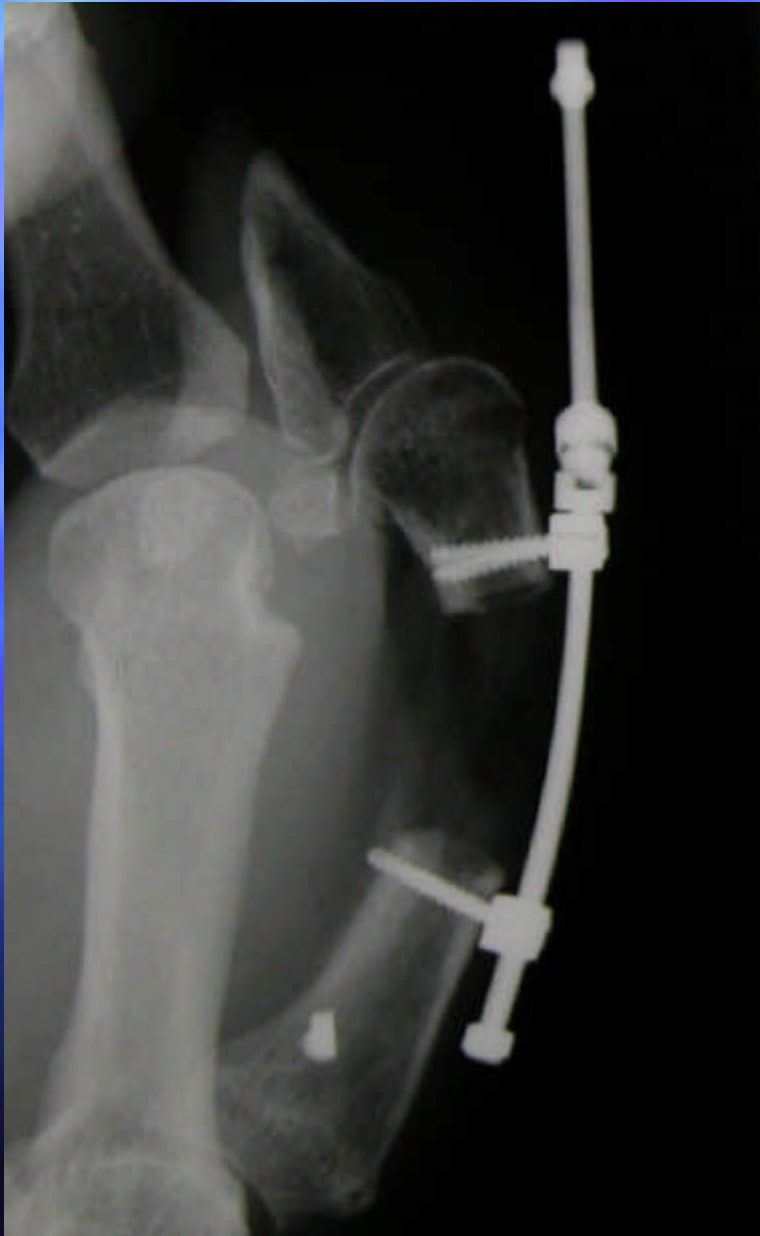Verwendung eines neuen internen  
Fingerdistraktors für Kallusdistraktion  
(erlaubt eine Verlängerung von 30 oder 23 mm)

Ausgangssituation









Zustand 6 Wochen nach  
Kallusdistraction